



# Management of retrorectal supralelevator abscess—results of a large cohort

Patrick Téoule<sup>1</sup> · Steffen Seyfried<sup>1</sup> · Andreas Joos<sup>2</sup> · Dieter Bussen<sup>2</sup> · Alexander Herold<sup>2</sup>

Accepted: 22 May 2018  
© Springer-Verlag GmbH Germany, part of Springer Nature 2018

## Abstract

**Purpose** Proximal intersphincteric fistulas with proximal extension causing supralelevatoric, retrorectal abscesses are a rare disease. There is only very limited experience, with small groups, and the limited published literature confirms the complexity of diagnostics and treatment. The aim of this study was to evaluate transrectal internal abscess drainage as planned definitive treatment. **Methods** We retrospectively studied medical records of all patients with the diagnosis of retrorectal abscesses that underwent transrectal internal abscess drainage in the Department of Colo-proctology of the University Medical Centre Mannheim (2003–2012). **Results** One hundred nine patients were operated on retrorectal abscesses, 70 (64.2%) men and 39 (35.8%) women. Mean age was 45.3 years (18–81). In 96 cases (88.1%), only a transrectal internal abscess drainage was performed as planned definitive treatment. Primary healing occurred in 60 patients (62.5%). A second transrectal internal drainage procedure was necessary in 27 cases (28.1%) to assure complete internal drainage. All secondary procedures led to subsequent healing. A combined surgical treatment due to coexisting fistula tracts to the perianal skin or additional ischioanal abscesses was required in 13 patients (11.9%), and an additional seton placement was performed. Nine patients (9.4%) underwent one or more reoperations due to previously unidentified complex coexisting fistulas. Most of these patients were immunosuppressed due to Crohn's disease. Internal drainage alone was successful in 90.6% with an overall healing rate of 94.5% for the entire population of complex fistulas. **Conclusions** Transrectal internal abscess drainage is a safe and highly successful procedure for treatment of retrorectal abscess, with very low risk of postoperative fecal incontinence. Inflammatory bowel disease and immunosuppressives have a negative impact on the healing process.

**Keywords** Transanal internal abscess drainage · Retrorectal abscess · Intersphincteric fistula

## Introduction

Anal abscesses and fistulas are a common surgical condition. The cryptoglandular theory of Eisenhammer and Parks is the widely accepted pathophysiologic mechanism for development

of these fistulas [1, 2]. Abscesses can be classified as perianal, ischioanal, intersphincteric, and supralelevator/retrorectal. In 1934, Milligan and Morgan and later Stelzner, as well as Goligher and Eisenhammer, described initial classifications of fistulas [3, 4]. Nowadays, the modified classification by Parks published in 1976, based on the course of the fistula in relation to the anal sphincters—inter-, trans-, supra-, and extrasphincteric—is the most widely used and accepted [5]. Management of the majority of anal abscesses and fistulas is straightforward and is based on the knowledge of the anatomy of the anorectum and adherence to establish surgical principles. In most of the cases, adequate surgical drainage is sufficient, reliable, safe, and feasible. On the contrary, intersphincteric abscesses can be difficult to diagnose. The usual external clinical signs of perirectal abscesses, such as swelling and induration of the perianal region, may not be present [6–8]. The majority of these fistulas track distally and are also fairly easily managed with typical surgical strategies. Proximal extension

---

Patrick Téoule and Steffen Seyfried contributed equally to this work.

**Electronic supplementary material** The online version of this article (<https://doi.org/10.1007/s00384-018-3094-7>) contains supplementary material, which is available to authorized users.

---

✉ Patrick Téoule  
patrick.teoule@umm.de

<sup>1</sup> Department of Surgery, University Medical Centre Mannheim, Medical Faculty Mannheim, Heidelberg University, Theodor-Kutzer-Ufer 1-3, 68167 Mannheim, Germany

<sup>2</sup> Deutsches End- und Dickdarmzentrum, Mannheim, Germany

within the intersphincteric and supralelevator planes can create a very challenging problem. A lay open technique for these retrorectal abscesses with high proximal extension may require division of the proximal internal anal sphincter, risking incontinence [9–11]. There had been great enthusiasm for ligation of intersphincteric tract (LIFT) and even BioLIFT procedures, but recently, these results had a poor outcome [12]. The transrectal internal abscess drainage provides a potentially safer and reliable treatment approach for these retrorectal abscesses. There is very limited experience published in the literature, often based on case reports with only small numbers of patients. There are anecdotal references to these abscesses as a source of pelvic sepsis in colorectal surgical texts. The aim of this retrospective study was to evaluate the results of transrectal internal abscess drainage as planned definitive treatment for this disease.

## Patients and methods

### Patients

Medical and operative reports of all patients treated for retrorectal abscess (Fig. 1) at the Department of Coloproctology of the University Medical Centre Mannheim, Medical Faculty Mannheim, Heidelberg University, during the period from February 2003 to July 2012, were analyzed

retrospectively. Patients with coexisting anal abscesses or fistulas were also included. All patients were treated by transrectal internal abscess drainage  $\pm$  another surgical procedure if required for additional fistula extensions. All abscesses were above the levator outside of the rectum in the vast majority dorsally. The internal orifice is mostly at the dentate line. Patient and fistula characteristics as well as fistula recurrence and fecal continence were collected from medical charts. The postoperative fecal continence was assessed by using the Rockwood Fecal Incontinence Severity Index.

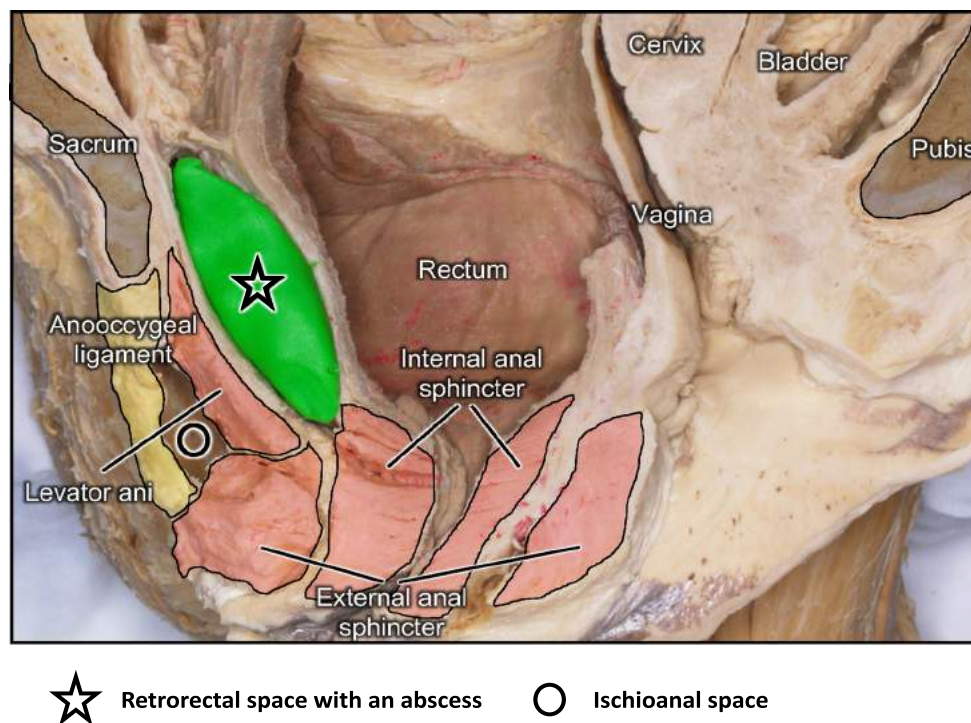
### Data collection and statistical analysis

Demographic characteristics and patients' medical records were collected and analyzed retrospectively for this study. Postoperative events and clinical outcomes were also recorded. Statistical analysis was performed using SPSS 15.0 (SPSS, Inc., Chicago, IL) statistical software.

### Treatment

Before treatment, individual diagnostics evaluated the patient to access the diagnosis. Here, proctoscopy, rectoscopy, and digital examinations were facilitated in all patients. If necessary, endoanal ultrasound, CT, or MRI scans were used. After accurate preoperative assessment of the chronic fistula

**Fig. 1** Cadaver situs with supralelevator abscess



**Source and permission:**

Prof. Dr. Thilo Thilo Wedel,  
Zentrum für Klinische Anatomie, Anatomisches Institut, Christian-Albrechts-Universität Kiel

anatomy, an elective procedure was planned. In only a very few cases, this was an emergency operation.

Via a transanal-transrectal route, the position of the abscess was palpated. Using Parks or Ferguson retractors, the operation field was exposed (Fig. 2). In all cases, an internal opening of the cavity could be found directly at or proximal of the dentate line, through this orifice the cavity was probed with a straight small probe (Fig. 3). Along this probe, the proximal anal canal and the distal rectum were incised. This incision was enlarged with curvilinear excision of the rectal bowel wall on both sides of the incision. The excision was made as long as necessary to drain the retroperitoneal part behind the rectum (Fig. 4). The excision should be large enough to create sufficient drainage (e.g., 5 × 8 cm) of the cavity. This internal wound was left completely open for secondary healing (Fig. 5). No special wound care was required due to the internal location of the wound. Outpatient follow-up was done in 2- to 3-week intervals. If the internal drainage was assessed to be closing prematurely, a repeat transanal drainage was performed and the internal opening enlarged. In those cases where external fistula openings were found in the perianal area, the fistula tract was evaluated with probing and in addition to the internal drainage, a silicon seton was placed. This seton was left in place for several weeks till complete internal healing was achieved. If required, a second procedure was performed to address this remaining fistula.

## Results

### Demographics

One hundred nine patients, 70 (64.2%) men and 39 (35.8%) women, were treated and underwent surgery at our department over a 10-year period. Mean age was 45.3 years (range 18–81). The incidence of a chronic inflammatory bowel disease was 24% (20.2% Crohn's disease). Patients' demographics

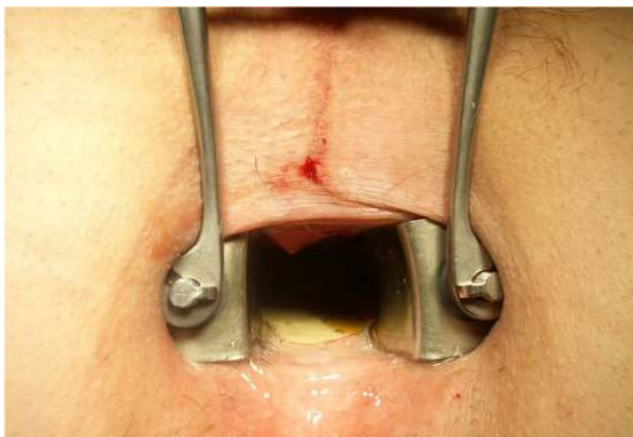


Fig. 2 Intraoperative situs before surgery

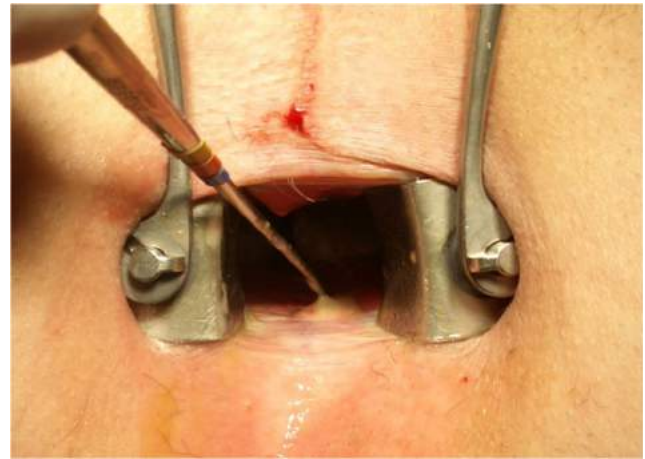

Fig. 3 Intraoperative situs with the internal opening at the dentate line

are summarized in Table 1. Interestingly, 39 (35.8%) patients suffered previously from an anal fissure. In declining order, other previous proctological diseases of patients were perianal abscess, cryptoglandular anal fistula, hemorrhoidal disease, mucosal prolapse, skin tags, and perianal ulceration (Table 2).

### Surgery and healing

All patients received an internal drainage as treatment. In 96 cases (88.1%), a transrectal internal abscess drainage was initially performed as planned definitive treatment. Primary healing with only one-step surgery was observed in 60 patients (62.5%). Revisional surgery was necessary in 27 cases (28.1%) to improve internal drainage, all of them with subsequent healing. Nine patients (9.4%) underwent one or more reoperations due to previously not identified complex coexisting fistulas. Most of these patients were immunosuppressed due to Crohn's disease. A combined surgical treatment due for coexisting fistulas or abscesses were required in 13 patients (11.9%): in these cases, an additional seton placement was performed. Healing following internal

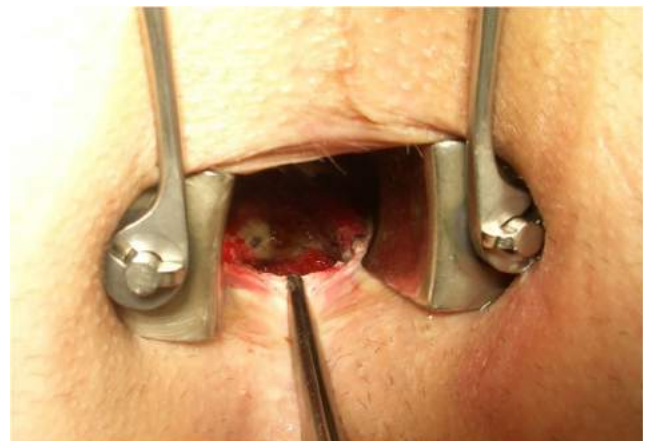
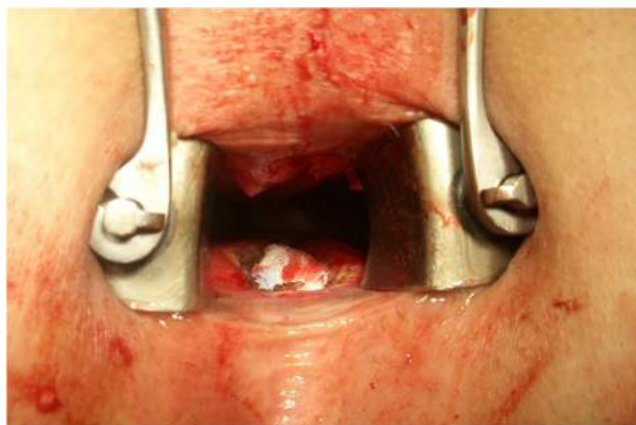

Fig. 4 Intraoperative situs after deroofing and enlarging of the abscess



**Fig. 5** Postoperative situs

drainage was successful in 90.6%. The overall healing rate was 94.5% for all fistula presentations. The flowchart gives an overview about postoperative results and healing rate (Flowchart). Twenty (18.3%) patients suffered from one or more complications. In declining order, new fistulas, continence disorder, new abscesses, bleeding, and fever occurred postoperatively. In total, 36 (33.0) reoperations were necessary (Table 3).

The most common localization of the abscess was posterior with 78.9%. Twenty-two (20.2%) patients suffered from a lateral abscess, and only one (0.9%) patient had an anterior localization. Accordingly, the posterior localization of the inner fistula ostium was the commonest with 88.1% (Table 4).

**Table 1** Patient cohort demographics and clinical data

	<i>n</i> = 109 (%)
Male/female sex	70 (64.2)/39 (35.8)
Age years (range)	45.3 (18–81)
Crohn's disease	22 (20.2)
Immunosuppressive medication	14 (12.8)
Ulcerative colitis	4 (3.7)
Immunosuppressive medication	1 (0.9)
Lymphoma or leukemia	3 (3.7)
Patients with immunosuppressive drugs	18 (16.5)
Hypertension	6 (5.5)
Preoperative diabetes mellitus	4 (3.7)
Others*	9 (8.2)
Preoperative symptoms <sup>x</sup>	
Perianal pain	70 (64.2)
Transanal secretion	63 (57.8)
Pruritus ani	41 (37.6)
Perianal pressure sensation	25 (22.9)
Bleeding	10 (9.2)
Fever	2 (1.8)

\*Cardiovascular disease, pulmonal disease, psychiatric disorder

<sup>x</sup> Multiple answers are possible

**Table 2** Previous proctological diseases

	<i>n</i> = 109 (%)
Anal fissure	39 (35.8)
Perianal abscess	28 (25.7)
Cryptoglandular anal fistula	23 (21.1)
Hemorrhoidal disease	17 (15.6)
Mucosal prolapse	6 (5.5)
Skin tags	5 (4.6)
Perianal ulceration	1 (0.9)

In declining order, inter-, trans-, supra-, and extrasphincteric fistulas were identified intraoperatively (Table 5).

Most patients underwent elective surgical procedures. Healing of the fistula was defined as complete wound healing with absence of symptoms. In 67 (61.4%) cases, the healing was complete after 12 weeks. After 24 weeks, the healing was complete in 80 (73.4%) patients including patients who underwent additional surgery caused by revision or complex fistulas. In 19 (17.4%) cases, the healing took longer or was not successful. The average of follow-up was 13.6 weeks (range 4–85).

## Discussion

The principals of management of supraleatory abscess (SLA) were clearly described in the 1970s and 1980s before the development of imaging techniques [5]. According to the described treatment principles, the suitable choice for the drainage route, either transrectal or perineal, is defined by the origin of the internal opening leading to the supraleatory abscess (i.e., either intersphincteric or ischiorectal). It is crucial to choose the appropriate route for abscess drainage to avoid potential morbidity resulting from sphincter damage or creation of even more complex fistula tracts. Some authors

**Table 3** Postoperative complications and reinterventions

	<i>n</i> = 109 (%)
Patients with complications*	20 (18.3)
Fever	2 (1.8)
Bleeding	4 (3.7)
New abscess	5 (4.6)
New fistula	9 (8.2)
Continence disorder <sup>x</sup>	7 (6.4)
Revisional surgery	36 (33.0)

\*Multiple answers are possible

<sup>x</sup> Grades I–II according to the Rockwood Fecal Incontinence Severity Index

**Table 4** Intraoperative findings

Localization: abscess		<i>n</i> = 109 (%)
Anterior		1 (0.9)
Posterior		86 (78.9)
Lateral		22 (20.2)
2–5 h		13 (12.0)
9–11 h		9 (8.2)
Localization: inner fistula ostium		
Anterior		1 (0.9)
Posterior*		96 (88.1)
Lateral		12 (11.0)
2–5 h		7 (6.4)
9–11 h		5 (4.6)

\*Patients who were only treated by internal drainage

recommend the use of drainage catheters to avoid these risks [13].

Our data demonstrates that internal drainage is a simple and safe method to treat retrorectal abscesses with a secure and very satisfactory cure rate of 90.6%. When internal drainage alone is the treatment, there is only a minimal risk of incontinence as there was no or only minimal proximal incision of proximal internal sphincter muscle. No external sphincter muscle was divided. In addition, this approach provides healing within 12 weeks for most patients with no need for complex wound management or associated morbidity of such a wound. They can therefore return to normal activity in a matter of weeks. In our knowledge, this is the largest series of treatment retrorectal abscesses by internal drainage to be published. As previously described, it is highly efficient to drain a retrorectal abscess through the rectum [14, 15]. Subsequent management may include opening the intersphincteric space through the rectum by dividing the internal anal sphincter. If necessary, an additional external drainage should be performed by using an ischioanal approach with or without seton placement. By performing this external drainage, the morbidity was also minimal as no extensive (muscle) tissue cutting was performed. In reference to other techniques, to perform an internal drainage, such as described by Garcia-Granero et al. [16] (by using an endostapler) or the placement of an artificial catheter (mushroom drainage or similar), the principal goals of the treatment is similar but economically more efficient with no issues of wound management by the patient.

**Table 5** Type of fistula

		<i>n</i> = 109 (%)
Intersphincteric		87 (79.8)
Transsphincteric		16 (14.6)
Suprasphincteric		4 (3.7)
Extrasphincteric		2 (1.8)

## Conclusions

All supralelevator abscesses should be evaluated and treated formally in the operating room setting. As shown with our cohort, internal drainage of retrorectal abscesses is safe, avoids expensive devices or drainage tubes, creates minimal wound issues, and is highly effective in curing the abscess/fistula. The technique can be used in association with other strategies required for related fistula tracts.

**Authors' contributions** PT, SS, and AH participated in the conception and design of the study. PT, SS, and AH performed the research, analyzed the data, and drafted the manuscript. AJ and DB participated in the revision of the manuscript. All authors have read and approved the final manuscript.

## Compliance with ethical standards

**Competing interests** The authors declare that they have no competing interests.

**Informed consent** Informed consent was obtained from all individual participants included in the study.

## References

- Eisenhammer S (1956) The internal anal sphincter and the anorectal abscess. *Surg Gynecol Obstet* 103:501–506
- Parks AG (1961) Pathogenesis and treatment of fistula-in-ano. *Br Med J* 1:463–469
- Eisenhammer S (1978) The final evaluation and classification of the surgical treatment of the primary anorectal cryptoglandular intermuscular (intersphincteric) fistulous abscess and fistula. *Dis Colon Rectum* 21:237–254
- Rickard MJ (2005) Anal abscesses and fistulas. *ANZ J Surg* 75:64–72. <https://doi.org/10.1111/j.1445-2197.2005.03280.x>
- Parks AG, Gordon PH, Hardcastle JD (1976) A classification of fistula-in-ano. *Br J Surg* 63:1–12
- Hyman N (1999) Anorectal abscess and fistula. *Prim Care* 26:69–80
- Nelson R (2002) Anorectal abscess fistula: what do we know? *Surg Clin North Am* 82:1139–1151 v–vi
- Rosen L (1994) Anorectal abscess-fistulae. *Surg Clin North Am* 74:1293–1308
- Prasad ML, Read DR, Abcarian H (1981) Supralelevator abscess: diagnosis and treatment. *Dis Colon Rectum* 24:456–461
- Bernard D, Tasse D, Morgan S (1983) High intermuscular anal abscess and fistula: analysis of 25 cases. *Can J Surg* 26:136–139
- Parks AG, Thomson JP (1973) Intersphincteric abscess. *Br Med J* 2:537–539
- Wallin UG, Mellgren AF, Madoff RD, Goldberg SM (2012) Does ligation of the intersphincteric fistula tract raise the bar in fistula surgery? *Dis Colon Rectum* 55:1173–1178. <https://doi.org/10.1097/DCR.0b013e318266edf3>
- Beck DE, Fazio VW, Lavery IC et al (1988) Catheter drainage of ischioanal abscesses. *South Med J* 81:444–446
- Garcia-Granero A, Granero-Castro P, Frasson M, Flor-Lorente B, Carreño O, Espí A, Puchades I, Garcia-Granero E (2014) Management of cryptoglandular supralelevator abscesses in the

- magnetic resonance imaging era: a case series. *Int J Color Dis* 29: 1557–1564. <https://doi.org/10.1007/s00384-014-2028-2>
15. Millan M, Garcia-Granero E, Esclapez P et al (2006) Management of intersphincteric abscesses. *Color Dis* 8:777–780. <https://doi.org/10.1111/j.1463-1318.2006.01035.x>
  16. Garcia-Granero A, Granero-Castro P, Frasson M et al (2014) The use of an endostapler in the treatment of supralelevator abscess of intersphincteric origin. *Color Dis* 16:O335–O338. <https://doi.org/10.1111/codi.12670>